Oral Radiology (2020) 36:40–46
https://doi.org/10.1007/s11282-019-00378-1

ORIGINAL ARTICLE

Prevalence of pneumatization of the articular eminence and glenoid fossa viewed on cone-beam computed tomography examinations in a Turkish sample

Gülay Altan Şallı[1] · İlknur Özcan[2] · Filiz Namdar Pekiner[3]

Received: 15 November 2018 / Accepted: 1 February 2019 / Published online: 22 February 2019
© Japanese Society for Oral and Maxillofacial Radiology and Springer Nature Singapore Pte Ltd. 2019

Abstract

Objective The aim of this study is to evaluate the prevalence of the pneumatization of the articular eminence and glenoid fossa (PAT and PGF, respectively) using cone-beam computed tomography (CBCT).

Methods CBCT images of 1000 patients (511 females and 489 males) representing 2000 regions of interest (the glenoid fossa and articular eminence of each patient) were examined retrospectively with regard to age, gender, laterality, and type of pneumatization. The mean age of the female patients was 39.66 and that of males was 39.79. Suitable images from patients aged 16 years and over found in the archives of CBCT images were included in the study. The data were assessed using IBM SPSS 20 and statistical comparisons between two categorical variables were conducted using Chi square tests.

Results It was observed that 14.7% of the patients had PAT and 47.1% had PGF. There was no significant difference in PAT and PGF prevalence between ages, age ranges, and gender in our study ($p > 0.5$).

Conclusions It is important to evaluate the pneumatic cells in the articular eminence and glenoid fossa regions before surgery. It was also found that CBCT is more helpful in detecting pneumatization than plain film.

Keywords Temporal bone · Pneumatization · Articular eminence · Glenoid fossa · Cone-beam computed tomography

Introduction

Pneumatization is the presence of an air-filled, epithelium-lined cavity in the bone that arises due to epithelial infiltration during bone development [1, 2]. These cavities can be observed in various bones but are most commonly found in the skull [1]. The temporal bone, which is part of the temporomandibular joint (TMJ) complex, is a particularly important bone in dentistry. It is composed of four sections: the squamous, petromastoid, tympanic, and styloid processes. Pneumatization of the squamous, petromastoid, and tympanic parts of the zygoma may extend to the articular eminence [2]. In fact, pneumatization has been reported in ten different regions of the temporal bone, including the zygomatic arch, glenoid fossa, and articular eminence [3, 4].

Temporal bone pneumatization starts during the fetal period and is largely completed by 9–10 years of age. The tympanic antrum appears in the 22nd week of fetal life and reaches its maximum size by the 35th week. Pneumatization begins in the petrous apex in the 28th week and in the 33rd week for the mastoid bone; in the 5th year, pneumatic cells become visible in the mastoid region [2, 5, 6]. According to other research, mastoid cells are all formed by around 10 years of age and maturation is complete at around 15–20 years old [7].

A pneumatized articular eminence (PAT), first described by Tyndall and Matteson, is an air-containing area similar to that in the mastoid and ethmoid bone that is observed in the articular eminence or zygomatic arch. As described by Tyndall and Matteson, the common traits

This study has been presented as an oral presentation in International Congress on Preventive Dentistry in Erzurum, Turkey, 2018.

✉ Gülay Altan Şallı
gulayaltan@beykent.edu.tr

[1] Department of Oral and Maxillofacial Radiology, Faculty of Dentistry, Beykent University, Avalon Campus, F416, Beylikduzu, Istanbul, Turkey

[2] Department of Oral and Maxillofacial Radiology, Faculty of Dentistry, Istanbul University, Istanbul, Turkey

[3] Department of Oral and Maxillofacial Radiology, Faculty of Dentistry, Marmara University, Istanbul, Turkey

of a PAT are that it is asymptomatic, is similar to mastoid air cells, is located in the temporal bone's zygomatic process, is observed as a radiolucent defect, reaches out to the articular eminence but does not cross the zygomaticotemporal suture, does not cause cortical defects, and does not expand onto the zygoma [8, 9].

Pneumatization of the articular eminence (PAT) and glenoid fossa (PGF) can lead to inflammation, tumors, and fractures in the joint. Pathologies such as ear and mastoid process tumors may extend to the TMJ. Otitis and mastoiditis reaching the TMJ region may result in ankylosis of the TMJ. The development of TMJ ankylosis at a young age leads to secondary effects on mandibular growth, such as malocclusion, facial asymmetry, and mandibular retrusion [10–12]. In addition, the presence of pneumatization causes inflammation to spread faster. PAT and PGF can also increase the risk of complications in TMJ surgery, so it is important to identify their presence so that the necessary precautions can be taken before surgery and the optimal surgical procedures applied.

Lindenmuth and Clark stated that surgeons should consider the details of PAT and PGF before surgery on these regions [13]. For example, if an osteotome is used during the operation, care should be taken to prevent the sudden penetration of the pneumatization. In addition, to ensure that there is no undiagnosed dural tear following the completion of the surgical procedure, the anesthetist should instruct the patient to conduct the Valsalva maneuver to confirm that cerebrospinal fluid has not leaked into the cavity. If a small dural tear is present, it can be covered with fascia or muscle obtained from the temporal region that has already been opened. The bone defect must also be closed [14–16].

Cone-beam computerized tomography (CBCT) is a safe method widely used in dentistry to obtain three-dimensional images of the jaw. It is particularly useful for PAT and PGF research because of its ability to provide high-resolution images and detailed scans in three dimensions (i.e., the coronal, sagittal, and axial planes) and its ability to provide cross-sections at the same time. However, a review of the published literature reveals that only two studies, one of which was conducted on a Turkish sample, have been assessed separately PAT and PGF using CBCT [1, 17]. As such, studies in this field on the Turkish population are limited. The aim of this study was thus to investigate the prevalence of PAT and PGF in a Turkish subpopulation by age, gender, laterality, and type of pneumatization using CBCT to make progress in this area and to form the basis for new research.

Materials and methods

Data from patients referred to the Department of Oral and Maxillofacial Radiology, Faculty of Dentistry, Marmara University for various reasons (e.g., impacted tooth, temporomandibular disorder, and implant or orthodontic planning) from 2012 to 2014 were retrospectively examined and 1000 patients aged 16 years and older were selected as the study group. Patients with systemic or metabolic bone disease, trauma anamnesis, maxillofacial deformation, or a history of surgery on the dentofacial region were excluded from the study group. The study protocol (17.12.2014, Decree No. 2) was approved by the Istanbul University Faculty of Dentistry Ethical Committee.

The same technician took all of the CBCT images using the same radiographic equipment (Planmeca Promax SD Mid CBCT device, Helsinki, Finland, at 90 kV, 12 mA, and a voxel size of 0.2 mm). The field of view (FOV) of the images assessed in this study was 16 × 16 cm. The Romexis 2.92 software program (Planmeca Oy, Helsinki, Finland) was used to reconstruct and evaluate the projections. The data were saved and exported as a single-frame DICOM file. The images were assessed directly on a 15.6-inch Full HD LED (1920 × 1080) pixel monitor (Asus N56VZ-S4283H, ASUSTeK Computer Inc., Beitou District, Taipei, Taiwan) with an NVIDIA GeForce GT 650M 4 GB screen cart. The images were evaluated using coronal, axial, sagittal, and, if necessary, reformatted oblique slices. No filter was added to the images. A clinician and a specialist (G.A.Ş and İ.Ö., respectively) who were working in the Department of Oral and Maxillofacial Radiology evaluated the radiological images in a darkened, quiet room.

A radiolucent area was classified as a PAT/PGF if it met the following criteria outlined by Tyndall and Matteson:

1. Asymptomatic radiolucent defect in the zygomatic process of the temporal bone similar to a mastoid air cell.
2. Extension of the bone defect as far as the articular eminence but not beyond the zygomaticotemporal suture.
3. No enlargement or cortical destruction of the zygoma [18].

Both sides of each patient were assessed separately. Pneumatization was recorded as unilateral when it was found on one side and bilateral when it was found on both. For pneumatization type, the classifications were unilocular for a single defect area with well defined borders and multilocular for numerous small radiolucent cavities. Age and gender were also recorded.

For the statistical analysis of the results, SPSS 20 (IBM, New York, USA) for Windows was used. Comparisons between two different categorical groups were conducted

using Chi square tests. Significance was set at $p < 0.05$. Intra- and inter-examiner calibration based on the anatomic diagnosis of CBCT images had been previously performed to assess data reliability. The observers evaluated the same images twice, with a 1-week interval between assessments. Wilcoxon's matched-pairs signed rank test was used to determine intra-examiner reliability, while inter-examiner reliability was assessed using the intraclass correlation coefficient (ICC) and the coefficient of variation (CV). The results revealed no intra-examiner variance between the observers ($p > 0.05$), with the ICCs between the two ranging from 0.917 to 0.934. There was also high inter-examiner agreement. The high ICC and low CV demonstrated that the CBCT assessment process was standardized between observers. No significant difference was seen in any of the variables ($p > 0.05$).

Results

The sample size for the study was 1000 patients (511 females and 489 males) providing 2000 regions of interest (i.e., the glenoid fossa and articular eminence of all patients). The age of the patients ranged from 16 to 77, and the mean age for the female patients was 39.66 and that for the males was 39.79. Overall, it was found that 14.7% of the patients in this study exhibited PAT ($n = 147$) and 47.1% exhibited PGF ($n = 471$).

Of the patients found with PAT, 85 were unilateral (57.8%) and 62 (42.2%) bilateral. Of these, 30 (35.3%) of the unilateral PAT cases were observed on the right and 55 (64.7%) on the left. In addition, 21 (14.3%) of the PAT cases were unilocular (Fig. 1) and 126 (85.7%) were multilocular. For PGF, 152 (32.3%) of the PGF cases were unilateral and 319 (67.7%) were bilateral. Of the unilateral PGF cases, 58 (38.2%) were on the right and 94 (61.8%) were on the left. Only 21 of the PGF cases (4.5%) were unilocular, while 450 (95.5%) were multilocular (Table 1; Figs. 2, 3).

There was no significant difference between the genders in PAT or PGF occurrence. Of the 147 patients with PAT, 73 (49.7%) were female and 74 (50.3%) were male patients ($p = 0.705$), compared to 245 (52.2%) female and 226 (48.0%) male PGF patients ($p = 0.584$; Table 2).

Of the patients with PAT in this study ($n = 147$), 8 were aged between 0 and 19 years, 32 were between 20 and 29 years, 45 were between 30 and 39 years, 24 were between 40 and 49 years, 26 were between 50 and 59, and 12 were over 60 years old. Of the 471 cases with PGF, 13 were aged between 0 and 19 years, 126 were aged between 20 and 29, 115 were aged between 30 and 39, 89 were aged between 40 and 49, 77 were aged between 50 and 59, and 51 were over 60 years old (Table 3). There was no statistical relationship between age and PAT or PGF prevalence.



Fig. 1 Unilocular PAT on a sagittal section

Table 1 Prevalence of the PAT, PGF, and types

	PAT	%	PGF	%
	147	14.7	471	47.1
Bilateral/unilateral				
Unilateral	85	57.8	152	32.3
Bilateral	62	42.2	319	67.7
Unilateral				
Right	30	35.3	58	38.2
Left	55	64.7	94	61.8
Type				
Unilocular	21	14.3	21	4.5
Multilocular	126	85.7	450	95.5

PAT pneumatized articular eminence, *PGF* pneumatized glenoid fossa

In addition to the data above, we investigated PAT and PGF cases in a Medline search (Tables 4, 5).

Chi square tests found no significant effect of age, age range, or gender on PAT and PGF prevalence ($p > 0.5$). The unilateral-to-bilateral ratio of PAT was 1.3:1, a result that was statistically significant ($p < 0.001$). Of the PGF cases, 67.7% were bilateral ($p < 0.001$). The Unilateral PAT and PGF cases were most common on the left side ($p < 0.001$). Multilocular PAT and PGF cases were much higher than unilocular ($p < 0.001$).

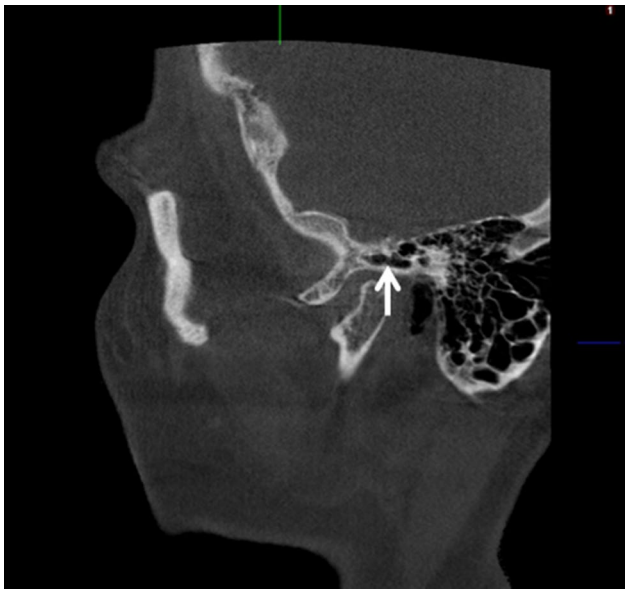

Fig. 2 Multilocular PGF on a sagittal section



Fig. 3 Multilocular PAT + PGF on a sagittal section

Table 2 Distribution among genders of PAT and PGF

Gender	PAT	PGF	PAT + PGF
Female	73 (49.7%)	245 (52.0%)	253 (51.8%)
Male	74 (50.3%)	226 (48.0%)	235 (48.2%)
p	0.705	0.584	0.646

PAT pneumatized articular eminence, *PGF* pneumatized glenoid fossa

Discussion

Pneumatization refers to air-filled cavities that develop in bone. These cavities can occur in different areas of the craniofacial bones [3]. The development of air cells before the formation of bone gaps is a physiological process associated with periosteal activity. After epithelial mucous membrane invagination, it undergoes atrophy, facilitating the growth of air cells by leaving a thin residual membrane layer and facilitating subepithelial bone resorption [14].

In 1976, Roser et al. described a formation they encountered when examining a TMJ in a panoramic radiograph as "a rare bony lesion of the zygomatic arch" [19]. In 1982, Kulikowski et al. reported that a patient who had their articular eminence surgically removed to treat chronic condylar subluxation had air cells in their zygomatic arch [20].

The process of temporal bone pneumatization is typically complete by 10 years of age in females and 15 years in males [2]. Another study suggests that mastoid air cells have formed completely by the age of 10, but the maturation stage only ends at 15–20 years old [7]. In the present study, patients younger than 16 years old were not included in the assessment of pneumatization. The selection of the study group age was similar to İlgüy et al., Miloglu et al., Tyndall et al., and Carter et al., in which the minimum ages were 15, 17, 17, and 15, respectively [1, 4, 18, 21].

The female-to-male ratio for PAT/PGF lesions exhibits some variability between studies. For example, the female-to-male ratio was 0.98 for Yavuz et al. and 1.6 for Miloglu et al. [4, 22]. In the present study, this ratio for PAT cases was 0.98, which is in agreement with the results of Ladeira et al., Tyndall and Matteson, and Yavuz et al. [17, 18, 22]. In Ilgüy et al.'s study, the proportion of female patients with PAT (73.6%) was higher than that of male patients (51.3%; $p < 0.05$) [1]. Similarly, in Shokri et al.'s study, 33 (33.6%) of the 98 patients were male and 65 (66.4%) were female [23].

Pneumatization begins during maturation or postnatal growth. Since puberty for girls occurs earlier than for boys, pneumatization in females is biologically more advanced than in men of the same age. Orhan et al. believed that this was the likely reason why PAT was more frequently observed in women than in men [23, 24].

The unilateral-to-bilateral ratio was 1.3:1 and similar to the literature [16, 21, 23–25]. Miloğlu et al., Shokri et al., and Kishore et al. all found that unilateral PAT was more common than bilateral PAT [4, 23, 25]. However, in Ilgüy et al.'s study, bilateral PAT was more commonly observed than unilateral PAT [1]. Previous researches have not reported a predisposing factor that affects the occurrence of unilateral or bilateral PAT [1, 14].

In the present study, 30 (35.3%) of the unilateral PAT cases were observed on the right and 55 (64.7%) on the left.

Table 3 Age distribution of the PAT/PGF cases among the ages group

Age groups	16–19	20–29	30–39	40–49	50–59	60+	Total
PAT	8	32	45	24	26	12	147
PGF	13	126	115	89	77	51	471

PAT pneumatized articular eminence, *PGF* pneumatized glenoid fossa

Table 4 Figures of PAT case series in a Medline search, plus in the present series

Case series	Patient (no)	PAT (no)	Male (no/%)	Female (no/%)	Age range	PAT prevalence (%)	Unilateral (no/%)	Bilateral (no/%)	Technique
Tyndal and Matteson [18]	1061	28	13 (46.4)	15 (53.6)	15–75	2.6	23 (82.1)	5 (17.9)	Panoramic
Kaugars et al. [15]	784	8	1 (12.5)	7 (87.5)	32–69	1.0	4 (50)	4 (50)	Panoramic
Carter et al. [21]	2734	40	20 (50.0)	20 (5.0)	17–83	1.5	32 (80.0)	8 (20.0)	Panoramic
Hofmann et al. [16]	1084	20	9 (45.0)	11 (55.0)	7–87	1.8	16 (80.0)	4 (20.0)	Panoramic
Orhan et al. [14]	1006	19	7 (36.9)	12 (63.1)	11–90	1.9	12 (63.1)	7 (36.9)	Panoramic
Orhan et al. [9]	1049	17	9 (53.0)	8 (47.0)	7–16	1.62	10 (58.9)	7 (41.1)	Panoramic
Yavuz et al. [22]	8107	83	42 (50.6)	41 (49.4)	10–75	1.03	56 (67.5)	27 (32.5)	Panoramic
Orhan et al. [24]	1405	48	12 (25.0)	36 (75.0)	9–20	3.42	32 (68.8)	16 (31.2)	Panoramic
Miloğlu et al. [4]	514	41	16 (39.0)	25 (61.0)	15–62	8	31 (75.6)	10 (24.4)	CBCT
Ladeira et al. [17]	658	140	257 (39)	401 (61)	11–85	21.3	76 (54.3)	64 (45.7)	CBCT
Shokri et al. [23]	1563	98	642 (41.1)	921 (58.9)	8–60	6.2	64 (65.3)	34 (34.7)	Panoramic
İlgüy et al. [1]	111	73	39 (35.1)	72 (64.9)	17–81	65.8	31 (27.9)	42 (37.8)	CBCT
Khojastepour et al. [26]	327	251	139 (55.4)	112 (44.6)	7–65	76.7	76 (30.3)	175 (69.7)	CBCT
Bhalchim et al. [27]	3000	59	34 (57.6)	25 (42.4)	5–91	1.96	66.6%	33.89%	Panoramic
Bhalchim et al. [27]	200	25	17 (68)	8 (32)	10–73	12.5	44%	56%	CBCT
Present series	1000	147	74 (50.3)	73 (49.7)	16–77	14.7	85 (57.8)	62 (42.2)	CBCT

PAT pneumatized articular eminence

Table 5 Figures of PGF case series in a Medline search, plus in the present series

Case series	Patient (no)	PGF (no)	Male (no)	Female (no)	Age range	PGF prevalence (%)	Unilateral (no/%)	Bilateral (no/%)	Technique
Groell and Fleismann [28]	100	51			14–88	51			CBCT
Ladeira et al. [17]	658	397	146	251	11–85	38.3	107 (42.5)	145 (57.5)	CBCT
İlgüy et al. [1]	111	16				11.7	10 (9.0)	3 (2.7)	CBCT
Present series	1000	471	226	245	16–77	47.1	58 (38.2)	94 (61.8)	CBCT

PGF pneumatized glenoid fossa

This result is consistent with the results of research by Kaugars and Ladeira et al. [15, 17]. In a study conducted by Orhan et al. in 2005, the proportion of unilateral PAT cases on the right side was higher than the left side [14]. However, in research by Hofmann, Carter, Yavuz, Shokri, and Khojastepour there were no statistically significant differences

in terms of pneumatization between the right and left sides [16, 21–23, 26]. Again, no mechanism has been proposed in past research to explain what might cause PAT to occur on the right or left side in terms of laterality.

Past research has reported various proportions of PAT type (i.e., unilocular or multilocular). In Miloğlu et al.'s study, 42.5% of all PAT cases were recorded as unilocular and 58.5% as multilocular [4]. Similarly, Orhan et al. reported that 38.5% of PAT cases were unilocular and 61.5% multilocular [14]. Multilocular PAT (74.7%) was much higher than unilocular PAT (25.3%) in the other study conducted by Orhan et al. [24] In contrast, Shokri et al. found a ratio of 53.1% unilocular-to-46.9% multilocular for PAT cases [23].

In our study, 21 (14.3%) of the PAT cases were unilocular and 126 (85.7%) were multilocular. This result is in agreement with research by Ilgüy and Ladeira et al. [1, 17] possibly because these two studies also assessed PAT using CBCT. Panoramic radiography is thought to be inadequate in determining the type of pneumatization because of disadvantages such as superpositions and limited detailing [1, 17]. In support of this, Bhalchim et al. reported that the prevalence of PAT found using panoramic radiography was only 1.96%, compared to 12.5% for CBCT [27].

PAT and PGF were assessed separately in this study. PGF was detected in 471 patients (47.1%). The results of our study accords with the rates of PGF reported in Ladeira et al. and Groell and Fleischmann [17, 28]. Of the PGF cases, 67.7% were bilateral and again agrees with Ladeira et al. (42.5% unilateral, 57.5% bilateral) [17]. In the study by Ilgüy et al., unilateral PGF was more common than bilateral PGF [1]. In the literature, no predisposing factor has been identified that can influence the likelihood of unilateral or bilateral PGF [1].

PGF cases were most common on the left side (61.8%) in our study. These results were similar to Ladeira et al. (29% right, 70% left) [17]. Previous research has yet to propose a mechanism that would cause PGF to be on the right or left side in terms of laterality [15, 17]. In addition, 95.5% of the PGF cases were multifocal and the results agreed with İlgüy and Ladeira et al. [1, 17], both of which also employed CBCT assessment.

Hemangioma, aneurysmal bone cysts, giant cell tumors, eosinophilic granuloma, metastatic tumors, and fibrous dysplasia all have an expansive or destructive nature. In contrast, PAT/PGF shows no expansion or bony destruction, an observation that can aid in differential diagnosis. Due to their asymptomatic nature, PAT/PGF conditions are diagnosed incidentally [14, 23], and no treatment is required. However, based on the minimal bone resistance in pneumatized areas, PAT/PGF may facilitate the spread of inflammation, tumors, or fractures. PAT is also considered a complicating factor in articular eminence surgery because of the high penetration risk of the osteotome into the middle cranial fossa [1, 23, 29]. PGF may also be a risk factor in TMJ surgery [1]. Since our study focuses only on prevalence, the presence of pathology in the relevant regions has not been investigated.

Previous research evaluated air cavities in the TMJ using panoramic radiographs or multislice computed tomography (MSCT). Panoramic radiographs lead to too many superpositions and thus appear not to be suitable for the detection of those pneumatization [1]. In contrast, using CBCT, Ladeira [17] and Groell and Fleischmann [28] reported a prevalence of PAT (21.3% and 51.0%, respectively) that was higher than previous studies that relied on panoramic radiography. In our study, CBCT was also employed and 14.7% of patients were found to have PAT. As with the other two studies, our figure is high compared to the PAT rates found in studies that utilized panoramic radiography where the prevalence ranges from 1 to 6.2% [9, 14–16, 18, 23–25, 28].

MSCT uses anisotropic voxel but CBCT uses isotropic voxels which offer a higher spatial resolution. Due to this, the reduction in slice thickness, and the consistency of its data for every major slice type, CBCT appears to be a more effective method for visualizing bone and air cavities than MSCT [2]. Though MRI is an excellent method for assessing the soft tissues of the TMJ, especially in the articular disc, CBCT remains the preferred method for the evaluation of the pneumatic areas and bone structures of the TMJ [21].

Conclusion

From a surgical point of view it has been reported that the evaluation of the pneumatization of the articular eminence and the glenoid fossa region of the temporal bone is important. The present study, based on CBCT examinations, shows, in a Turkish sample, the prevalence of those pneumatization, which is in line with other studies [4, 17, 22, 26, 27], and which demonstrate that this prevalence seems much higher than the numbers found in studies where panoramic radiographs were used.

Author contributions GAŞ and İÖ, conceptualized and designed the study, acquired, interpreted the data, drafted the manuscript, and revised the paper. FNP contributed to the data collection and revised the paper.

Funding The study was self-funded by the authors.

Compliance with ethical standards

Conflict of interest All authors declare that they have no conflict of interest.

Human and animal rights statement All procedures followed were in accordance with the ethical standards of the responsible committee on human experimentation (institutional and national) and with the Helsinki Declaration of 1964 and later versions. This article does not contain any studies with human or animal subjects performed by the any of the authors.

References

1. Ilgüy M, Dölekoğlu S, Fişekçioğlu E, Ersan N, İlgüy D. Evaluation of pneumatization in the articular eminence and roof of the glenoid fossa with cone-beam computed tomography. Balkan Med J. 2015;32(1):64–8.
2. Jadhav AB, Fellows D, Hand AR, Tadinada A, Lurie AG. Classification and volumetric analysis of temporal bone pneumatization using cone beam computed tomography. Oral Surg Oral Med Oral Pathol Oral Radiol. 2014;117(3):376–84.
3. Bronoosh P, Shakibafard A, Mokhtare MR, Munesi T. Temporal bone pneumatization: a computed tomography study of pneumatized articular tubercle. Clin Radiol. 2014;69(2):151–6.
4. Miloğlu O, Yılmaz AB, Yıldırım E, Akgül HM. Pneumatization of the articular eminence on cone beam computed tomography: prevalence, characteristics and review of the literature. Dentomaxillofac Radiol. 2011;40(2):110–4.
5. Balzeau A, Radovcić J. Variation and modalities of growth and development of the temporal bone pneumatization in Neandertals. J Hum Evol. 2008;54(5):546–67.
6. Görür K, Özcan C, Talas ÜD. The computed tomographical and tympanometrical evaluation of mastoid pneumatization and attic blockage in patients with chronic otitis media with effusion. Int J Pediatr Otorhinolaryngol. 2006;70(3):481–5.
7. Ilea A, Butnaru A, Sfrangeu SA, Hedeşiu M, Dudescu CM, Berce P, Chezan H, Hurubeanu L, Trombitaş VE, Câmpian RS, Albu S. Role of mastoid pneumatization in temporal bone fractures. AJNR Am J Neuroradiol. 2014;35(7):1398–404.
8. Tyndall D, Matteson S. The appearance of the zygomatic air cell defect (ZACD) on panoramic radiographs. Oral Surg Oral Med Oral Pathol. 1987;64:373–76.
9. Orhan K, Delilbasi C, Orhan AI. Radiographic evaluation of pneumatized articular eminence in a group of Turkish children. Dentomaxillofacial Radiol. 2006;35:365–70.
10. Kumar R, Hota A, Sikka K, Thakar A. Temporomandibular joint ankylosis consequent to ear suppuration. Indian J Otolaryngol Head Neck Surg. 2013;65:627–30.
11. Kaban LB, Perrott DH, Fisher K. A protocol for management of temporomandibular joint ankylosis. J Oral Maxillofac Surg. 1990;48:1145–51.
12. Chidzonga MM. Temporomandibular joint ankylosis: review of thirty-two cases. Br J Oral Maxillofac Surg. 1999;37:123–6.
13. Lindenmuth JE, Clark MS. Pneumatization of the articular eminence. Cranio. 1986;4:86–7.
14. Orhan K, Delilbasi C, Cebeci I, Paksoy C. Prevalence and variations of pneumatized articular eminence: a study from Turkey. Oral Surg Oral Med Oral Pathol Oral Radiol Endod. 2005;99:349–54.
15. Kaugars G, Mercuri L, Laskin D. Pneumatization of the articular eminence of the temporal bone: prevalence, development and surgical treatment. JADA. 1986;113:55–7.
16. Hofmann T, Friedrich RE, Wedl JS, Schmelzle R. Pneumatization of the zygomatic arch on pantomography. Mund Kiefer Gesichtschir. 2001;5:173–9.
17. Ladeira DB, Barbosa GL, Nascimento MC, Cruz AD, Freitas DQ, Almeida SM. Prevalence and characteristics of pneumatization of the temporal bone evaluated by cone beam computed tomography. Int J Oral Maxillofac Surg. 2013;42:771–5.
18. Tyndall DA, Matteson SR. Radiographic appearance and population distribution of the pneumatized articular eminence of the temporal bone. J Oral Maxillofac Surg. 1985;43(7):493–7.
19. Roser SM, Rudin DM, Brady FA. Unusual bony lesion of the zygomatic arch. J Oral Med. 1976;31:72–3.
20. Kulikowski BM, Schow SR, Kraut RA. Surgical management of a pneumatized articular eminence of the temporal bone. J Oral Maxillofac Surg. 1982;40:311–3.
21. Carter LC, Haller AD, Calamel AD, Pfaffenbach AC. Zygomatic air cell defect (ZACD) Prevalence and characteristics in a dental clinic outpatient population. Dentomaxillofacial Radiol. 1999;28:116.
22. Yavuz MS, Aras MH, Güngör H, Büyükkurt MC. Prevalence of the pneumatized articular eminence in the temporal bone. J Craniomaxillofac Surg. 2009;37(3):137–9.
23. Shokri A, Gangachin MN, Baharvand M, Mortazavi H. Prevalence and characteristics of pneumatized articular tubercle: first large series in Iranian people. Imaging Sci Dent. 2013;43:283–7.
24. Orhan K, Oz U, Orhan AI, Ulker AE, Delilbasi C, Akcam O. Investigation of pneumatized articular eminence in orthodontic malocclusions. Orthod Craniofac Res. 2010;13(1):56–60.
25. Kishore M, Panat SR, Kishore A, Aggarwal A, Upadhyay N, Agarwal N. Prevalence of zygomatic air cell defect using orthopantomogram. J Clin Diagn Res. 2015;9:9–11.
26. Khojastepour L, Paknahad M, Abdalipur V, Paknahad M. Prevalence and characteristics of articular eminence pneumatization: a cone-beam computed tomographic study. J Maxillofac Oral Surg. 2018;17(3):339–44.
27. Bhalchim SG, Jugade SC, Ramaswami E, Gogri AA, Kadam SG, Umarji HR. Prevalence of pneumatized articular tubercle using panoramic radiography and cone beam-computed tomography: a retrospective study. Contemp Clin Dent. 2018;9(2):221–6.
28. Groell R, Fleischmann B. The pneumatic spaces of the temporal bone: relationship to the temporomandibular joint. Dentomaxillofac Radiol. 1999;28:69–72.
29. Hasnaini M, Ng SY. Extensive temporal bone pneumatization: incidental finding in a patient with TMJ dysfunction. Dent Update. 2000;27(4):187–9.

Publisher's Note Springer Nature remains neutral with regard to jurisdictional claims in published maps and institutional affiliations.