Okajimas Folia Anat. Jpn., 73(2-3): 145-150, August, 1996

A Case Report; Trilobular Spleen?

By

Ahmet USTA, Bülent BAYRAKTAR, Kayihan ŞAHİNOĞLU, Çetin DERGIN and Başak KUMBASAR

Department of Anatomy, University of Istanbul, Istanbul Medical Faculty. 34390, Capa—Istanbul—Turkiye

—Received for Publication, September 25, 1995—

Key Words: Anomaly, lobular spleen, arterial segmentation

Summary: During dissection course a spleen with a pyramidal extremity was noted. Literature reviewed and this rare case has been presented.

A "normal" spleen varies greatly in size, shape and distribution of its vessels (Hollinshead, 1956; Lindner, 1989; Testut, 1931; Williams, 1989). Except accessory spleens, true anomalies of spleen are very rare (Blaustein, 1963; Hollinshead, 1956; Moore, 1988; Patten, 1953; Symmers, 1978; Wigglesworth, 1991; Williams, 1989). Association of the other system abnormalities is frequently present (Bharati *et al.*, 1976; Blaustein, 1963; O'Leary *et al.*, 1991; Peoples *et al.*, 1983).

Observations

A spleen with an anomalous extremity on its anterior pole was found in an 45 year-old Caucasian male who died of tuberculosis during a gross anatomy course at our department. The spleen with 15 × 8.6 × 14 cm in sizes and 330 gr. in weight was wedge-shaped and in its normal position (Williams, 1989) (Fig. 1). There were two notches of 0.5 cm in depth on its superior border and one notch of 6 cm in depth on inferior border (Fig. 2).

On visceral surface, just above the anterior extremity located one pyramidal-shaped extremity showed the following sizes; 4.5 × 2 × 6.5 × 8 cm. There was a notch of 3.5 cm in depth between the pyramid-like extremity and visceral surface of the spleen (Fig. 3).

Structure of this extremity was microscopically similar to the spleen, and its distal end adhered firmly to transverse colon by a thick ligament (splenocolic ligament, Callander, 1947; Anson, 1971) (Figs. 2 and 3). The splenic artery after arising from celiac trunk was running retropancreatically above the splenic vein and ending in hilum as two big terminal branches. The splenic artery gave off a branch to the extremitas posterior of the spleen 9 cm proximal to the splenic hilum, and two branches (6 cm proximal to the hilum), one to posterior part of inferior border of the spleen and other to greater curvatura of the stomach (arteria gastro-epiploica). The latter gave off a little branch to the distal part of the pyramid-like extremity of the spleen that arising from its omental branch. Almost at the level of termination of the splenic artery, it gave a fourth little branch to the base of the pyramid-like extremity (Figure 2 and 3)).

For better understanding, the pattern of segmentation of the spleen it was examined by corrosion cast technique. Corrosion cast of the vascular tree was obtained by a handinjecting plastic casting material (Technovit R, Kulzer & Co. GMBH 638 Bad Homburg v.d.H.). 35.5% HCI was used for masseration at room temperature. For this procedure injection was made into splenic artery at the level of the celiac trunk.

At the level of hilum, splenic artery was divided into two major (primary) branches; superior and inferior central arteries. Each primary branch gave off a segmental branch; superior and inferior polar arteries (Fig. 3).

Additionally, we found a doubled right renal artery in the same cadaver.

Discussion

A spleen is in shape of the segment of an orange (wedgeshaped) or tetrahedron. The superior edge is generally convex and it has one or two notches pointing out the fetal lobulation.

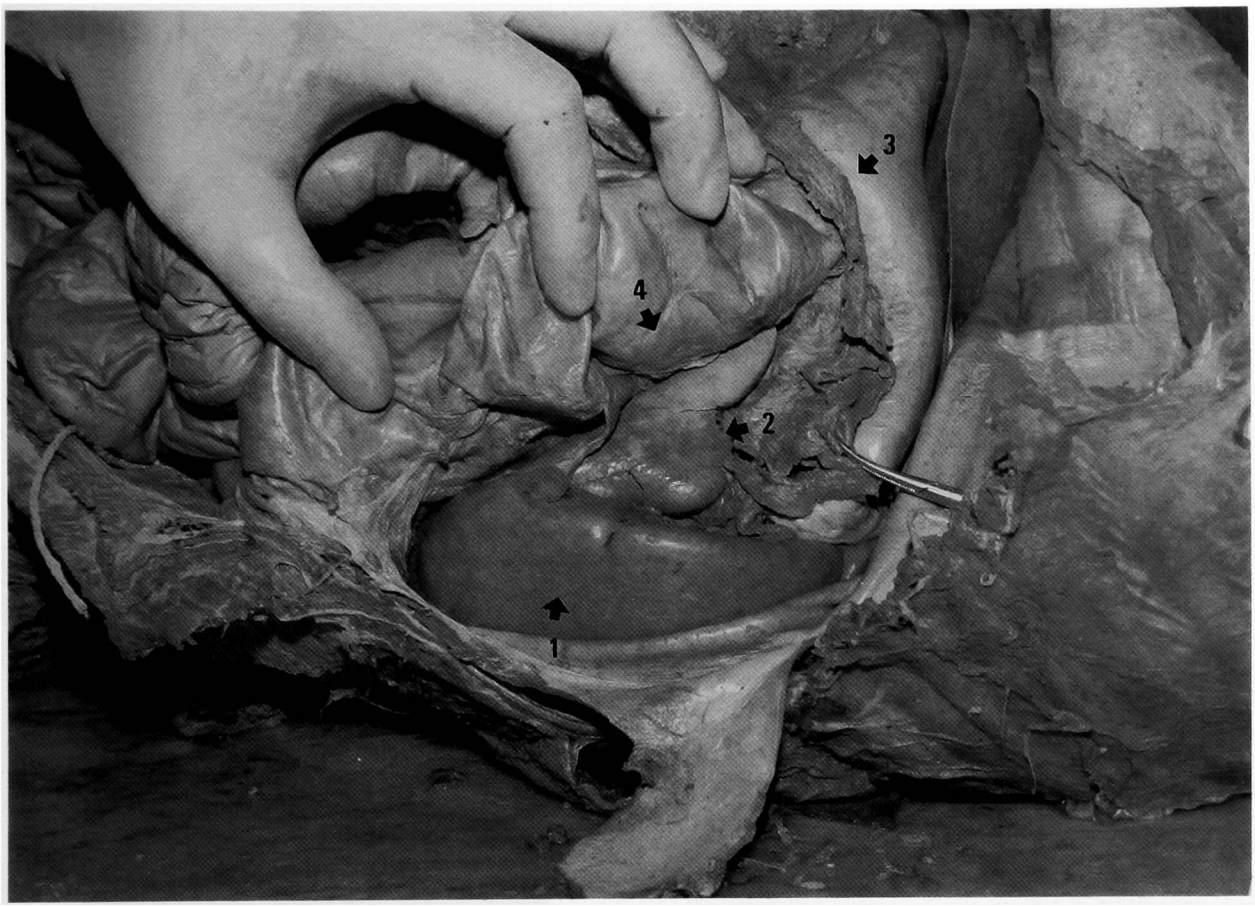

Fig. 1. Accessory splenic lobe between stomach and transverse colon. (1) spleen, (2) accessory lobe, (3) stomach, (4) transverse colon.

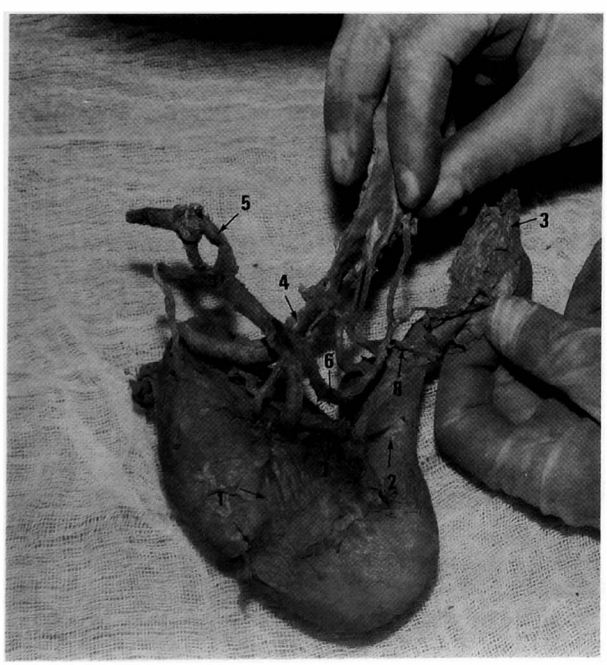

The inferior border is blunter than the superior one. The posterior extremity is rounded. The anterior extremity is more expanded than the posterior one.

Embryo of 8 mm exhibit a swelling on the left side of the mesogastrium. This bulge is due to an accumulation of mesenchymal cells. The accumulation of the mesenchymal cells takes place in the form of buds which unit and form the spleen plate in the sixth week. The notches in the border of the adult spleen are remnants of the grooves that separated the fetal lobules (Arey, 1948; Brandt, 1949; Gardner, 1960; Williams, 1989).

If the notches are deep, the spleen is lobulated. The spleen is in multiple form if some of the embryonic buds are not united. The splenic tissue which is

Fig. 2. Postero-inferior view of spleen. (1) notch on margo inferior (covered with splenic capsule), (2) accessory lobe, (3) a segment of transverse colon (near left flexure) (4) stomach, curvatura major, (5) a. lienalis, (6) a. gastro-epiploica sinistra, (7) arterial branch to proximal part of accessory lobe, (8) arterial branch to distal part of accessory lobe.

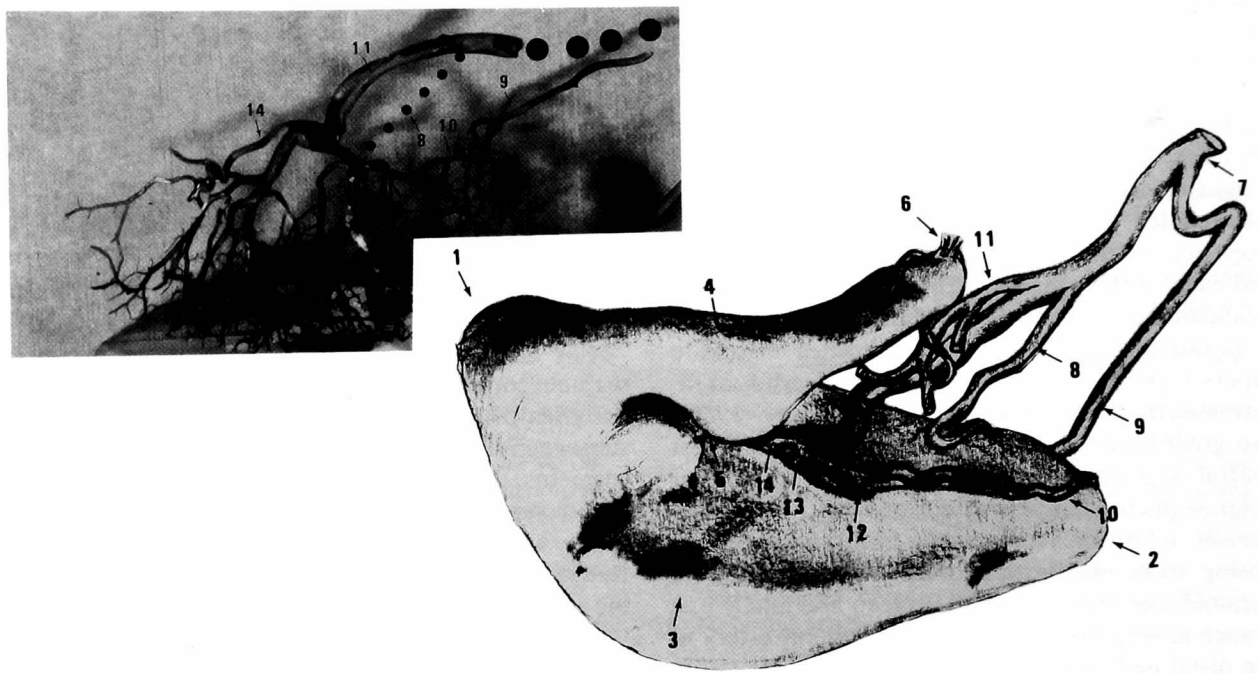

Fig. 3. Distribution of the a. lienalis; (1) extremitas anterior, (2) extremitas posterior, (3) margo superior (crenatus), (4) accessory lobe, (5) the notch between accessory lobe and spleen, (6) lig. splenocolicum, (7) a. lienalis, (8, 9, 10) subsegmental branches to superior polar segment, (11) a. gastroepiploica sinistra (one of its branches supplies distal part of accessory lobe), (12) superior central artery, (13) inferior central artery, (14) specific branch to proximal part of accessory lobe, (15) segmental branch to inferior polar segment. Upper left; corrosion cast model.

not incorporated into the organ is isolated as accessory spleen (spleniculi). Sometimes this accessory spleen may be connected to the spleen by a thin band of splenic tissue (Arey *et al.*, 1976; Brandt, 1949; Redmond *et al.*, 1989; Williams, 1989).

The congenital absence of spleen (splenic agenesis), congenital hypoplasia, lobulation, polysplenia, accessory spleen (spleniculi) are congenital malformation of the spleen. These anomalies are very rare except the accessory spleen which is seen in 10–30% (Blaustein, 1963; Moore, 1988; Symmers, 1978; Wigglesworth, 1991) in population, and they are mostly seen with other malformations. The heart and great artery anomalies are one of these frequent malformations (Bharati *et al.*, 1976; Blaustein, 1963; Hollinshead, 1956; Lindner, 1989; Mikhail *et al.*, 1979; Moore, 1988; O'Leary *et al.*, 1991; Peoples *et al.*, 1983; Symmers, 1978; Vandamme *et al.*, 1986; Williams, 1989).

According to Hollinshead, one can talk about the lobulated spleen in the presence of deep notches on superior border or both on superior and inferior borders (Hollinshead, 1956). A notch in 6 cm depth on the inferior edge of the spleen revealed that our case was a lobulated spleen.

We concerned the blood supply and the relation with the main spleen mass of the pyramid-like extremity of the spleen to decide whether it is an accessory spleen or not. This pyramid-like extremity was bound to the main mass by its wide base instead of a thin band of splenic tissue. Additionally, the most distal part of this extremity was attached to the transverse colon by a strong ligament (spleno-colic ligament Callander, 1947; Anson, 1971). And a deep notch between the extremity and the main mass made us that this extremity is an extension of the spleen instead of being an accessory spleen. The pyramid-like extremity received two arterial branches; one coming from left gastro-epiploic artery to supply the distal part of the extremity and the next coming from the main splenic artery trunk to supply the greater part of the extremity. But we did not observe any anastomosis between these two branches and the adjacent segmental arteries (inferior segmental artery).

We think that this accessory segment divided by a deep notch on the anterior border can be regarded as a third lobule.

Gupta and Dixon declared that arteria lienalis was divided into two (superior, inferior) or three (superior, medial, inferior) primary segmental branches (Gupta, 1976; Dixon, 1980). Anson and Callander mentioned about the superior polar, superior terminal and inferior terminal segmental

arteries (Anson, 1971; Callander, 1947). Mikhail and Garcia-Porrero reported that splenic artery could give off one superior polar, one to three inferior polar, two (superior, inferior) or three (superior, medial, inferior) terminal (primary) segmental branches (Mikhail, 1979; Garcia-Porrero, 1988). Vandamme and Redmond reported that splenic artery was divided into one superior polar, two central (superior, inferior) and one inferior polar branches and each of them supplied their segments of spleen (Vandamme *et al.*, 1986; Redmond *et al.*, 1989).

In our case, there are three branches leading to superior polar segment (a polaris superior or a. extremitatis lienalis posterioris-Vandamme, 1986), two great branches leading to superior and inferior central segments, one branch leading to inferior polar segment (a. polaris inferior or a. extremitatis lienalis inferioris-Vandamme, 1986), one branch arising from main trunk of splenic artery to the pyramid-like extremity of the spleen and finally one branch arising from the left gastro-epiploic artery to the distal part of the this extremity.

Gupta *et al.*, reported that the ratio of the existence of two primary branches was 84%, while Dixon observed it as 80%. (Gupta *et al.*, 1976; Dixon *et al.*, 1980). Both the two authors did not mention the existence of polar vessels. Garcia-Porrero has established this distribution as 92.82% and the presence of the superior and inferior polar segments as 10.49%. Also Garcia-Porrero has recorded the extension of superior polar artery from the main branch (a. lienalis) as 71.7%, the extension from the primary (major) branches as 70%, as for the inferior polar arteries respectively as 29.63% and 23.46%. Rarely they have stated that (2%) two or three inferior polar segments could be found (Garcia-Porrero *et al.*, 1988). Mikhail has stated the incidence of two terminal (primary) branches as 77%, the existence of both the superior and the inferior polar segments as 12% (Mikhail *et al.*, 1979). In our case one superior and one inferior polar segment were present.

Vandamme, Redmond, Anson and Callander have reported that the a. lienalis divides into two primary (major) branches and they have disagreed with the other writers' third primary branch findings.

Although Vandamme has reported the incidence of superior polar branch (a. extremitatis lienalis posterioris) as 52%, for the inferior polar branch he has merely stated that it is rarely seen and has not stated anything about the two polar branches existing at the same time or not.

Redmond classified the segmentary branches concerning their origins and he reported the ratio of superior polar segmentary artery originating from the main trunk of splenic artery was 39.8% and the ratio of the same artery originating from the central branch (a. splenica superior) was 62%. For the inferior polar segmentary artery these ratios were 14.5% and 28% (a. splenica inferior) consequently, and for the left gastro-epiploic artery 57.5%.

Redmond defined the segments of the spleen as anatomically distinct areas of splenic tissue running from the anterior to the posterior border, perpendicular to the long axis of the spleen and he also observed that they ranged in number from three to seven. He divided the segments into two morphological types and named them as "central" and "polar". On his further study, he noted that each segment consisted of a number of subsegments which had their own arteries and veins, and the number of subsegments are 3 in the polar, 4 in the central segments. He declared that the central segmental blood supply was constant, the polar segmental supply was more variable. Against the other authors, Redmond insisted on the polar segments, especially the inferior polar segments.

In our case, like Redmond's study, there were 2 central segments (superior, inferior), one superior and one inferior polar segments.

There are two branches directly coming from the main trunk of splenic artery, one from superior central branch, totally three branches leading to superior polar segment. After the masseration, it is observed that all these branches are subsegmental arteries (Redmond *et al.*, 1989).

In literature, the lobulated spleen anomaly was declared in a study of congenital cardiac anomalies. Bharati observed that tricuspit atresia was found with a deep-notched spleen in 0.9%, with a lobulated spleen in 0.5% (Bharati *et al.*, 1976).

It has not been encountered with literature with our trilobular case which has two polar, two central and one accessory segments.

The pyramidal-shaped extra-spleen tissue which is seen in our case has a specific artery, and this is an issue that has to be paid attention to, in surgeries.

References

1) Anson BJ and McVay CB. Surgical Anatomy. Vol. 1 W.B. Saunders Company, Philadelphia, London, Toronto 5th ed, 1971.
2) Arey LB. Developmental Anatomy. W.B. Saunders Company, Philadelphia, London, 5th ed, 1948.
3) Bharati S, McAllister HA, Tatooles CJ, Miller RA, Weinberg M, Bucheleres G and Lev M. Anatomic Variations in Underdeveloped Right ventricle Related to Tricuspid Atresia and Stenosis, J Thora Cardiovasc Surg 1976; **72**:3.
4) Blaustein A. The Spleen. McGraw-Hill Book Comp. Inc. New York, Toronto, London, 1963.
5) Brandt W. Lehrbuch der Embryologie. Verlag von S. arger, Basel, 1949.
6) Callander CN, Brunn H and Naffziger H. Surgical Anatomy, W. B. Saunders Comp. Philadelphia, London, 2nd ed, 1947.

7) Da Costa AC. Elements D'Embryologie. Masson & Cie, Paris, 1948.
8) Dixon JA, Miller F, McCloskey D and Siddoway J. Anatomy and Techniques in Segmental Splenectomy, Surgery, Gynecology & Obstetrics 1980; **150**:516.
9) Garcia-Porrero JA and Lemes A. Arterial Segmentation and Subsegmentation In The Human Spleen, Acta Anat 1988; **131**:276.
10) Gardner E, Gray DJ and O'Rahilly R. Anatomy, W.B. Saunders Comp. Philadelphia, London, 1960.
11) Gupta CD, Gupta SC, Arora AK and Singh PJ. Vascular Segments In The Human Spleen, J Anat 1976; **121**:3.
12) Hollinshead WH. Anatomy For Surgeons Volume 2 (The Thorax, Abdomen and Pelvis). Hoeber Harper, New York, 1956.
13) Lindner HH. Clinical Anatomy. Appleton and Lange, Connecticut, 1989.
14) Mikhail Y, Kamel R, Nawar NNY and Rafla MFM. Observations On The Mode Of Termination and Parenchymal Distribution Of The Splenic Artery with Evidence Of Splenic Lobation and Segmentation, J Anat, 1979.
15) Moore LK. The Developing Human. W.B. Saunders Company, Philadelphia, 1988.
16) O'Leary PW, Seward JB, Hagler DJ and Tajik AJ. Echocardiographic Documentation of Splenic Anatomy in Complex Congenital Heart Disease, The Am Jour of Cardiology 1991; **68**:1536–1538.
17) Patten BM. Human Embryology. McGraw-Hill Book Company, Inc., New York, Toronto, London, 2nd ed, 1953.
18) Peoples WM, Moller JH and Edwards JE. Polysplenia: A Review Of 146 Cases, Pediatric Cardiology 1983; **4**:2.
19) Redmond HP, Redmond JM, Rooney BP, Duignan JP and Bouchier-Hayes DJ. Surgical Anatomy Of The Human Spleen, Br J Surg 1989; **76**:2.
20) Symmers W St C. Systemic Pathology, Vol. 2. Churchill Livingstone, Edinburgh, London and New York. 2nd ed, 1978.
21) Testut L and Latarjet A. Trait, D'Anatomie Humaine. Gaston Dion, Paris, 1931.
22) Vandamme JPJ and Bonte J. Systematisation of the Arteries in the Splenic Hilus, Acta Anat 1986; **125**:217–224.
23) Wigglesworth JS and Singer DB. Textbook of Fetal and Perinatal Pathology, Vol. 1. Blackwell Scientific Publication, Oxford, London, Edinburgh, Melbourne, Paris, Berlin, Viena. 1991.
24) Williams LP, Warwick R, Dyson M and Bannister HL. Gray's Anatomy. Churchill Livingstone, Edinburgh, London, Melbourne and New York, 37th ed, 1989.