INTERNATIONAL AEGEAN SYMPOSIUMS on Natural & Medical Sciences-II

September 18-20, 2020 / Izmir, Turkey

Proceeding Book

Editor
Dr. Şükriye Neslihan ŞENEL

ISBN: 978-625-7139-67-0
by İSPEC Publishing house

The Clinical And Radiologic Examination Of The Patients With Paget's Disease Before Bisphosphonate Treatment

Dr. Şükriye Neslihan Şenel
Istanbul University Faculty of Dentistry, Department of Oral and Maxillofacial Radiolog, ORCİD No:0000-0002-9600-0819
Prof. Dr. İlknur ÖZCAN
Istanbul University Faculty of Dentistry, Department of Oral and Maxillofacial Radiology ORCİD No: 0000-0001-9006-5630

ABSTRACT
Paget's disease (PD) or "osteitis deformans" is a chronic progressive disease involving single bone (monostotic) or many bones (polyostotic) of the body. Clinical symptoms include pain, deformity, and may lead to fracture of the affected bone. The bones most frequently affected are in the spine, skull, pelvis and lower legs. The involvement of the maxilla or the mandible may cause the enlargement of the alveolar bones. The etiology of PD is still obscure, but genetic and environmental factors may play a role. Researchers have discovered several genes that may predispose individuals to developing Paget's disease. Genes associated with this condition are the sequestosome 1 gene, the TNFRSFIIA gene that codes for the RANK protein, and the VCP gene.

The diagnosis of Paget's disease may be confirmed by a thorough clinical evaluation, detailed patient history, blood tests and radiologic examination such as x-ray images and bone scintigraphy. The blood test may reveal elevated levels of the enzyme alkaline phosphatase suggesting the diagnosis of Paget's disease. Radiograph shows characteristic cotton wool appearance and other radiographic finding include well-circumscribed radiolucency, loss of lamina dura and hypercementosis. Therapeutic agents commonly used include calcitonin, bisphosphonate, and mithramycin. Bisphosphonates suppress or reduce bone resorption by osteoclasts. They do this both directly, by inhibiting the recruitment and function of osteoclasts and perhaps indirectly, by stimulating osteoblasts to produce an inhibitor of osteoclast formation. Intravenous adminstration of the Zoledronic acid is the preferred treatment. Zoledronic acid is not indicated for individuals with low blood calcium or vitamin D deficiency and those with a compromised renal function. Etidronate, tiludronate, alendronate, and risedronate are taken orally. In recent years, bisphosphonate related osteonecrosis of the jaws has become one of the most discussed adverse events in the treatment of osteoporosis and other bone diseases. Most cases of bisphosphonate osteonecrosis of the jaws occurs after trauma, such as tooth removal. For this reason, prior to treatment with bisphosphonates, the patient should have a thorough oral examination, any unsalvageable teeth should be removed, all invasive dental procedures should be completed, sharp bony prominences should be removed, and optimal periodontal health should be achieved.

In this study, we are reporting the clinical and radiologic examination of three patients with Paget's disease before bisphosphonate treatment.

Key words: Paget's disease, bisphosphonate treatment, clinical examination, radiologic findings.

Introduction

Paget's disease of bone (PDB), initially termed osteitis deformans, was first described by Sir James Paget in 1876 (Fishlock&Patel, 2018, 245, p. 245-252) . PDB is a chronic progressive disorder characterized by osteoclastic resorption and bone remodeling at one (monostotic) or more (polyostotic) skeletal sites. (Michou&Orcel, 2019, p.538-541). The bones most frequently affected are in the spine, skull, pelvis and lower legs. The involvement of the maxilla or the mandible may cause the enlargement of the alveolar bones (Ralston&Corral-Gudino, 2019, p. 579-604). The etiology of PDB is still obscure, but genetic and environmental factors may play a role. In approximately 15-30% of cases PDB shows

genetic inheritance. Genes associated with this condition are the Sequestosome 1 gene, the TNFRSFIIA gene that codes for the RANK protein, and the VCP gene (Altman, https://rarediseases.org/rare-diseases/pagets-disease/; Peeters&Ridder, 2019, p. 115044). At least 20-25% of PDB patients are asymptomatic. In many patients the main symptoms of Paget's disease are bone pain, joint pain and headache (Kravets, 2018, p. 1298-1303). These symptoms may cause some complications such as arthritis, hearing loss, spinal stenosis, pathologic fractures, cardiovascular complications and sarcomas in 0,2-1% patients (Fishlock&Patel, 2018, 245, p. 245-252).

The diagnosis of Paget's disease may be confirmed by a thorough clinical evaluation, detailed patient history, blood tests and radiologic examination. The most commonly used biochemical marker of Paget's disease of bone is the serum alkaline phosphatase level, the elevation of serum alkaline phosphatase is often the evidence of Paget's disease (Kravets, 2018, p. 1298-1303). Other biochemichal markers are procollagen type I N-terminal propeptide, serum C-telopeptide, urinary N-telopeptide, and urinary hydroxyproline (Kravets, 2018, p. 1298-1303; Olleros-Rodrìguez&Jacquart, 2019, p. 715-718). The most used used imaging techniques for PD are radiography, bone scintigraphy, CT, and MRI. Direct radiographs reveals a 'cotton wool' appearance indicating a mixture of osteolytic and osteoblastic areas (Kravets, 2018, p. 1298-1303). In the long bones, osteolysis is observed as a characteristic metaphyseal to diaphyseal wedge-shaped area of radiolucency that assumes the configuration of a flame or blade of grass. The computerized tomography of the skull, especially the frontal and occipital bones reveals large areas of radiolucency named as "osteoporosis circumscripta" (Theodorou&Theodorou, 2011, p. S64–S75).

The therapeutic agents mostly used include calcitonin, bisphosphonates, denosumab, and mithramycin. Bisphosphonates suppress or reduce bone resorption by osteoclasts (Fishlock&Patel, 2018, 245, p. 245-252). Intravenous adminstration of the Zoledronic acid is the preferred treatment. Zoledronic acid is not indicated for individuals with low blood calcium or vitamin D deficiency and those with a compromised renal function. Etidronate, tiludronate, alendronate, and risedronate are taken orally (Kravets, 2018, p. 1298-1303).

Case Reports

Case 1

Our first case was a 76 year female patient. She had hypertension and she was allergic to the Aspirine. The serum alkaline phosphatase level was 160 U/L. The internal medicine doctor sent the patient to our faculty for the evaluation of the Paget's disease.



Figure 1. The extraoral image of the patient In the extraoral examination we noticed the expansion of the mandible.

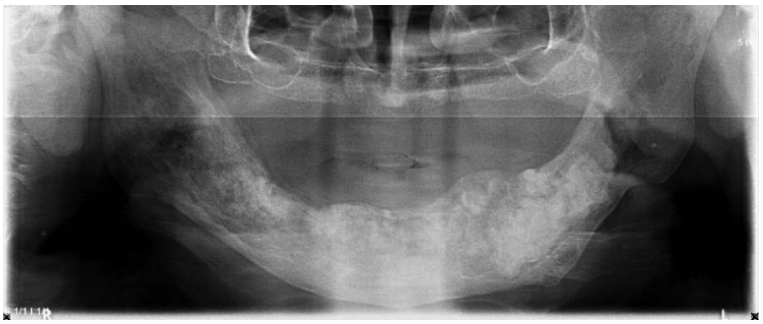

Figure 2. The Panoramic radiograph of the patient that taken in 2016. This image showed cotton-wool appaerence and expansion at the mandible.



Figure 3. The 3-d tomographic image (axial section) of the patient that taken in 2016. This image showed hyperdense lesions at the mandible. This appaerence verified the Paget's disease diagnosis.

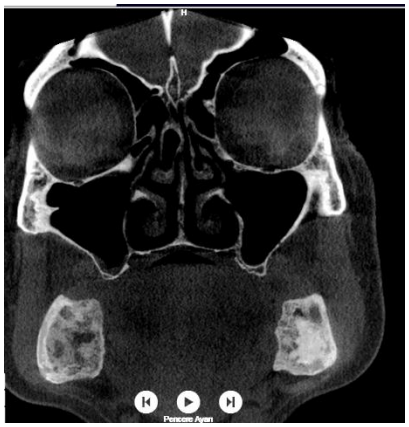

Figure 4. The 3-d tomographic image (coronal section) of the patient that taken in 2016. This image showed hyperdense lesions at the mandible and concha bullosa at the right.

After the patient was diagnosed with Paget's disease it was decided to apply bisphosphonate treatment. Dental treatment was not performed before bisphosphonate treatment, as there was no infection focus in this patient. The patient applied to our faculty in 2019 to have a new removable prosthesis.



Figure 5. The panoramic control radiograph of the patient that taken in 2019. This image showed that there wasn't osteonecrosis after bisphosphonate treatment at the mandible.



Figure 6. The intraoral image of the patient with her new removable prosthesis.

Case 2

Our second case was a 64 year old male patient. He had arrhythmia and used Metoprolol tartarate (Belok zok). He was diagnosed with Paget's disease 16 months ago. The internal doctor prescribed oral Risedroante (Actonel) one year ago for three months. The serum alkaline phospahatase level of the patient was 135 U/L and he applied to our faculty before bisphosphonate treatment for dental examination.

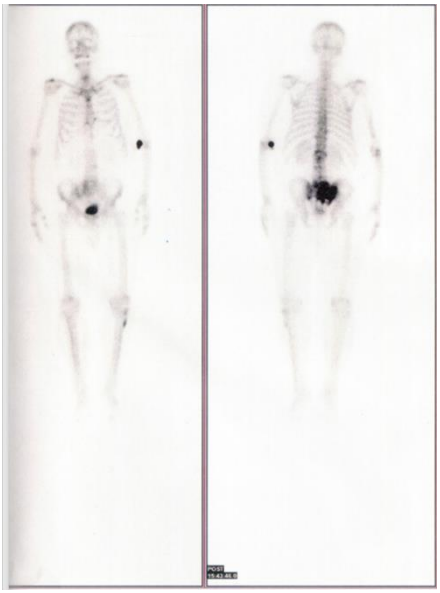

Figure 7. Whole body scintigraphy of the patient showed intense heterogenous increased activity at the posterior elements of 5. lomber vertebra and the spread of lytic-sclerotic areas at the sacrum and the iliac bone Also increased cortical activity at lateral of the left tibia raises suspicion of second focus.

This image shoved polyostotic lesions of Paget's disease.

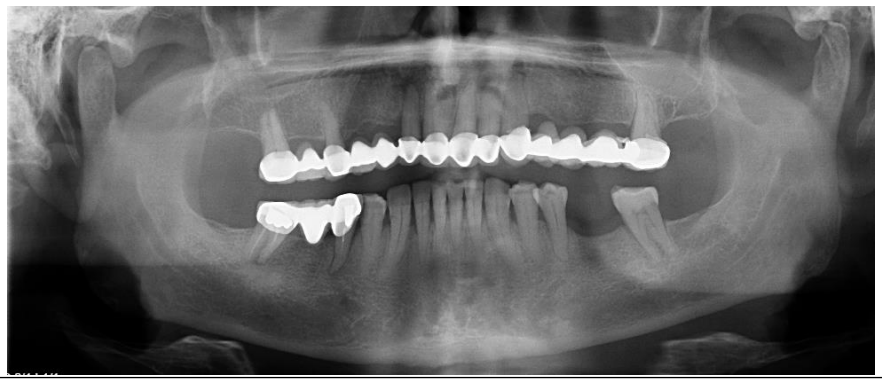

Figure 8. The panoramic radiograph of the patient. This image showed generalized periodontitis of gingivas.

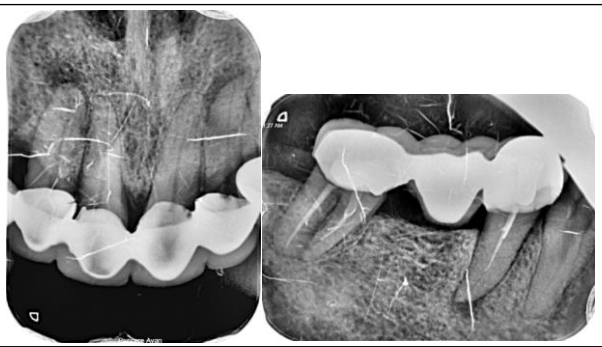

Figure 9 and 10. Periapical radiographs of the patient. These images showed apical lesions at the upper laterals and at the lower right second premolar.

We decided to finish the periodontal and endodontic treatment before bisphosphonate theraphy in order to avoid the risk of osteonecrosis.

Case 3

Our third case was a 65 year old male patient. He had poliomyelitis in his childhood. He had moderate aort valve and also mild mitral and tricuspid valve insufficiency. He was diagnosed Paget's disease and Osteoporosis 9 months ago. His serum alkaline phosphatase level was 150 U/L. He applied to our faculty before bisphosphonate treatment for dental examination.



Figure 11. The panoramic radiograph of the patient. This image showed generalized periodontitis and deep caries at the upper right second molar.

We decided to take a 3-d tomography to evaluate mandible for detection of cotton-wool appaerence.



Axial



Sagittal

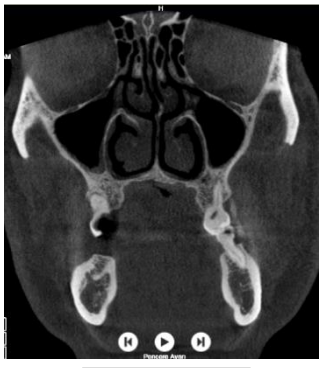

Coronal

Figure 12, 13 and 14. The 3-d tomographic image (axial, sagittal and coronal sections) of the patients. There wasn't an appaerence of cotton-wool in these images.

We decided to extract the decayed tooth and to finish the periodontal treatment before the bisphosphonate theraphy, but first of all we requested the consultation of the cardiologue about the antibiotic prophylaxy in order to avoid the risk of bacterial endocarditis.

Conclusion

In recent years, bisphosphonate related osteonecrosis of the jaws has become one of the most discussed adverse effects in the treatment of osteoporosis and Paget's disease (Wat, 2014, p. 977-983; Ralston&Corral-Gudino, 2019, p. 579-604). Most cases of bisphosphonate osteonecrosis of the jaws occurs after trauma, such as tooth removal. For this reason, prior to treatment with bisphosphonates, the patient should have a thorough oral examination, any unsalvageable teeth should be removed, all invasive dental procedures should be completed, sharp bony prominences should be removed, and optimal periodontal health should be ensured (Rollason&Laverrière, 2016, p. 1-35).

References

Fishlock A, Patel N. Paget's disease of bone. Orthopaedics and Trauma 2018; 32(4): 245-252.
Michou L, Orcel P. Has Paget's bone disease become rare? Joint Bone Spine 2019; 86(5): 538-541.
Ralston SH, Corral-Gudino L, Cooper C, Francis RM, Fraser WD, Gennari L, Guañabens N, Javaid MK, Layfield R, O'Neill TW, Russell RG, Stone MD, Simpson K, Wilkinson D, Willis R, Zillikens MC, Tuck SP. Diagnosis and Management of Paget's Disease of Bone in Adults: A Clinical Guideline. J Bone Miner Res. 2019; 34(4):579-604.
Altman RD. Paget's Disease. https://rarediseases.org/rare-diseases/pagets-disease/
Peeters JJM, Ridder RD, Hamoen EC, Eekhoff EMW, Smit F, Boudin E, Hul WV, Papapoulos SE, Appelman-Dijkstra NM. Familial Paget's disease of bone: Long-term follow-up of unaffected relatives with and without Sequestosome 1 mutations. Bone 2019; 128:115044.
Kravets I. Paget's Disease of Bone: Diagnosis and Treatment. Am J Med 2018; 131: 1298-1303.
Olleros Rodrìguez C, Jacquart DB, Arborio Pinel R, de la Piedra Gordo C, Moro Àlvarez MJ, Curiel MD. Long term effects on biochemical bone markers of a single infusion of zoledronic acid in Paget disease of bone. J Orthop Sci 2019; 25(4): 715-718.
Theodorou DJ, Theodorou SJ, Kakitsubata Y. AJR Integrative Imaging 2011; 196:S64–S75.
Wat WZM. Current perspectives on bisphosphonate treatment in Paget's disease of bone. Ther Clin Risk Manag 2014; 10: 977-983.
Rollason V, Laverrière A, MacDonald LCI, Walsh T, Tramèr MR, Vogt-Ferrier NB. Interventions for treating bisphosphonate-related osteonecrosis of the jaw (BRONJ). Cochrane Database of Systematic Reviews 2016; Issue 2. Art. No: CD008455, p.1-35.